



DIAGNOSTIC CHALLENGE

Check the correct answer on page 91

Case 1



Figure 1: MRI Pelvis

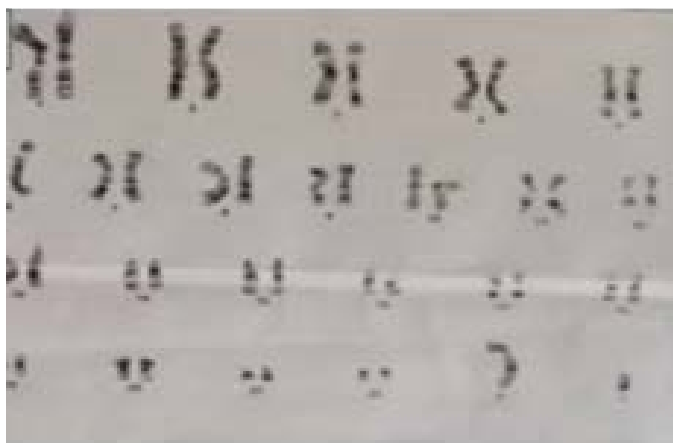


Figure 2: Chromosomal analysis

A 13 year old female referred from dermatology department with complaints of hirsutism and hoarseness of voice for last 1 year. Her menarche is not established yet. General physical examination revealed the type 3 hirsutism on Ferryman and Gallwey scale, with no secondary sexual characteristic. On inspection of vulva, clitoromegaly is noted.

What is your diagnosis?

Case 2

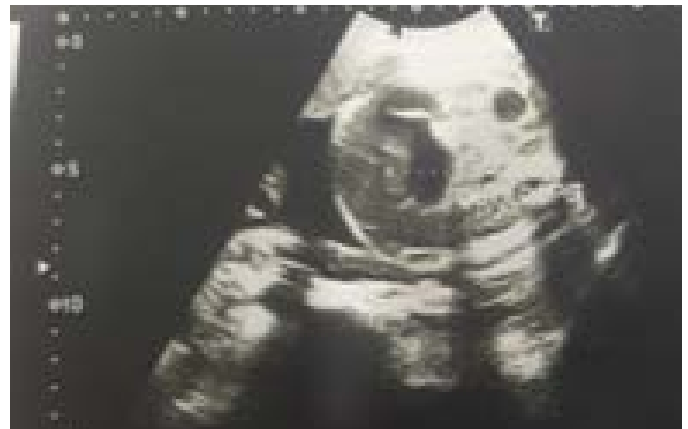

Figure 1: Fetal ultrasound

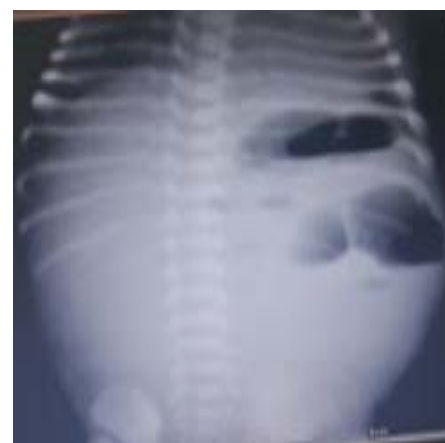

Figure 2: Neonatal X-ray Abdomen plain

A 32-year-old healthy primigravida with a normal pregnancy was scheduled for her 34th-week obstetric evaluation. The ultrasound showed a single fetus in cephalic presentation, with a normal weight for gestational age and with dilatation of gut loop. The amniotic fluid index was normal, and no other fetal anatomic anomalies were observed.

Correlate the pictures and give your diagnosis?