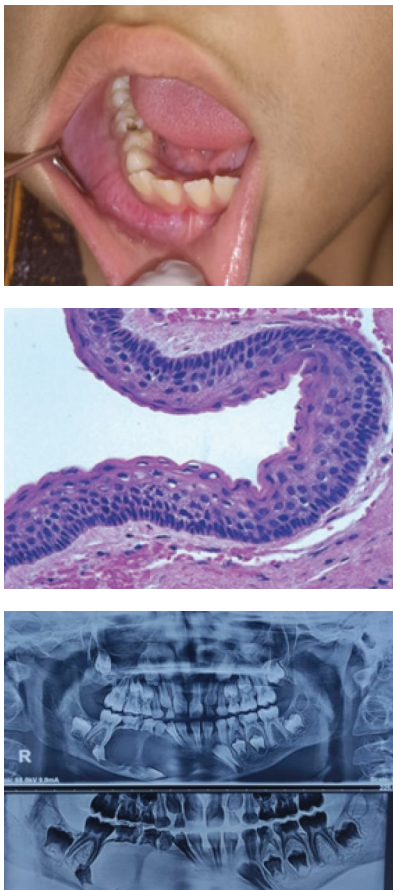


DIAGNOSTIC CHALLENGE

Check the correct answer on page 38

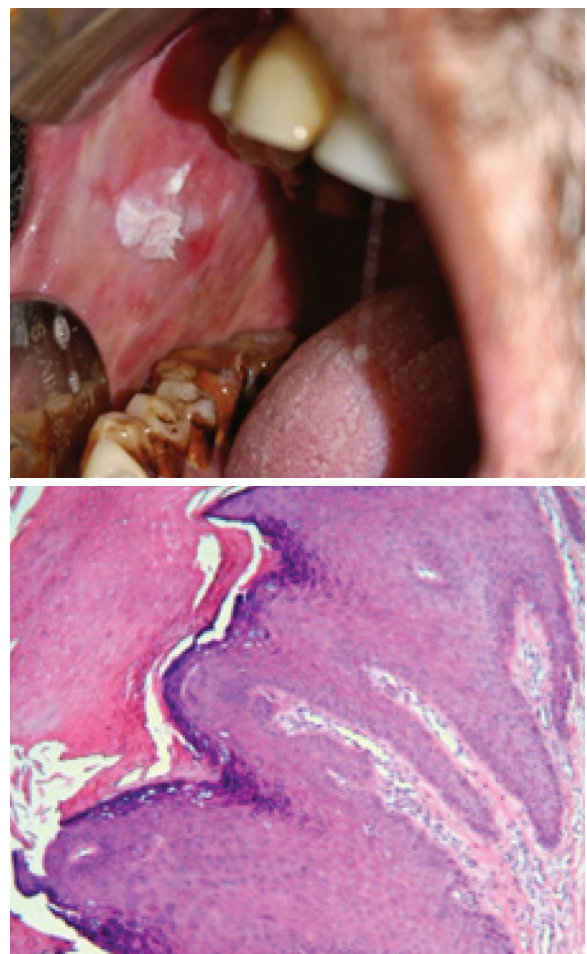
Case 1



An 8-year-old girl was referred to the oral and maxillofacial surgery department of HITEC dental hospital , Taxila, with a one-year history of increasing enlargement of the right jaw. The swelling was painless, with no associated complications. On examination multiple carious teeth were found. OPG revealed multilocular radiolucent lesion extending from left lower incisor to right lower 1st molar along with thinning of lower border of mandible.

What is your diagnosis?

Case 2



A 50-year-old male presented to the oral and maxillofacial department of HITEC dental hospital, Taxila, with a complaint of limited mouth opening. On examination intraoral fibrous palpable bands were present which are diagnostic for oral submucous fibrosis and a white lesion was observed which was exophytic and painless with associated mucosal discoloration. History revealed the patient to be a hepatitis C positive truck driver, doing betel nut and gutka chewing for the last 20 years.

What is your diagnosis?